Treatment of Stage 3A Lung Cancer

Gerard A. Silvestri MD,MS
Hillenbrand Professor of Thoracic Oncology
Medical University of South Carolina
Charleston, SC
Silvestri@musc.edu

CHEST® Congress 2019
Thailand
Bangkok | 10-12 April

Disclosures

- NOTE: All are Research Funding only
  - Patient Centered Outcomes Research Institute
  - NIH/NCI
  - Auris Medical
  - Boston scientific Corporation
  - Exact Sciences
  - Integrated Diagnostics/Biodesix
  - Olympus America
  - Oncimmune
  - Oncocyte
  - Prolung
  - Veracyte
  - Veran

Outline

- What is stage III non-small cell lung cancer (NSCLC)?
- Review conventional treatment for stage III NSCLC
- Highlight early data for immunotherapy NSCLC
- Special Circumstances

Staging

- Accurate staging is critical
  - Treatment options are stage dependent
  - Prognosis is based upon stage
  - Enrollment in clinical trials by stage
  - Provides a common language when discussing cases
  - Allows for study of large cohorts of patients

T (Primary Tumor)		Label
T0	No primary tumor	
Tis	Carcinoma in situ (Squamous or Adenocarcinoma)	
T1	Tumor ≤3 cm,	
T1a(mi)	Minimally Invasive Adenocarcinoma	
T1a	Tumor ≤1 cm	T1a $_{\leq 1}$
T1b	Tumor >1 but ≤2 cm	T1b $_{>1\text{-}2}$
T1c	Tumor >2 but ≤3 cm	T1c $_{>2\text{-}3}$
T2	Tumor >3 but ≤5 cm or tumor involving:	
	visceral pleura[a], (PL1,2)	T2 $_{Visc\ Pl}$
	main bronchus (not carina), atelectasis to hilum[a]	T2 $_{Centr}$
T2a	Tumor >3 but ≤4 cm	T2a $_{>3\text{-}4}$
T2b	Tumor >4 but ≤5 cm	T2b $_{>4\text{-}5}$
T3	Tumor >5 but ≤7 cm	T3 $_{>5\text{-}7}$
	or invading chest wall, pericardium, phrenic nerve	T3 $_{Inv}$
	or separate tumor nodule(s) in the same lobe	T3 $_{Satell}$
T4	Tumor >7 cm	T4 $_{>7}$
	or tumor invading: mediastinum, diaphragm, heart, great vessels, recurrent laryngeal nerve, carina, trachea, esophagus, spine;	T4 $_{Inv}$
	or tumor nodule(s) in a different ipsilateral lobe	T4 $_{Ipsi\ Nod}$

Stage IIIA

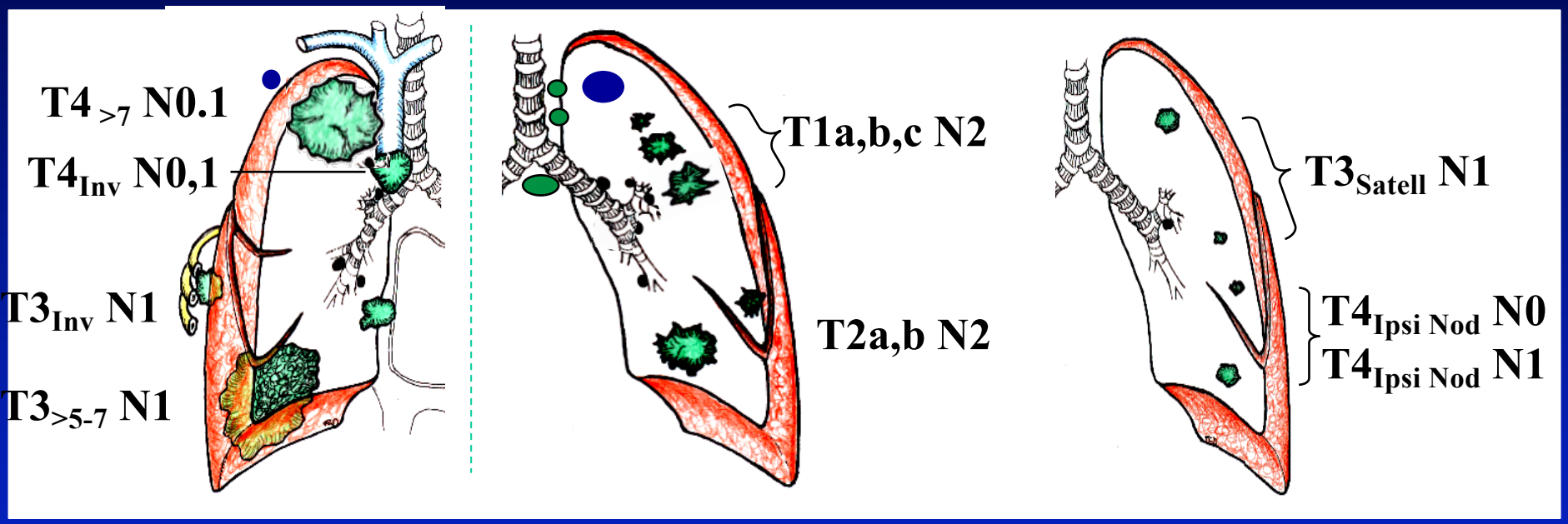

Key Feature:	T	N	Additional nodule

Case 1

- 79 yo F h/o COPD and tobacco use (20 pack-years) with growing RLL lung nodule (1.1 cm)

- Mediastinoscopy
  - Positive N2 node
  - Adenocarcinoma, +KRAS
  - Stage?

- cT1bN2M0
  - IIIA

T/M	Label	N0	N1	N2	N3
T1	T1a ≤1	IA1	IIB	IIIA	IIIB
	T1b >1-2	IA2	IIB	IIIA	IIIB
	T1c >2-3	IA3	IIB	IIIA	IIIB
T2	T2a *Cent, Visc Pl*	IB	IIB	IIIA	IIIB
	T2a >3-4	IB	IIB	IIIA	IIIB
	T2b >4-5	IIA	IIB	IIIA	IIIB
T3	T3 >5-7	IIB	IIIA	IIIB	IIIC
	T3 *Inv*	IIB	IIIA	IIIB	IIIC
	T3 *Satell*	IIB	IIIA	IIIB	IIIC
T4	T4 >7	IIIA	IIIA	IIIB	IIIC
	T4 *Inv*	IIIA	IIIA	IIIB	IIIC
	T4 *Ipsi Nod*	IIIA	IIIA	IIIB	IIIC
M1	M1a *Contr Nod*	IVA	IVA	IVA	IVA
	M1a *Pl Dissem*	IVA	IVA	IVA	IVA
	M1b *Single*	IVA	IVA	IVA	IVA
	M1c *Multi*	IVB	IVB	IVB	IVB

Case 1, continued

- Concurrent chemoradiation
  - Carboplatin/Paclitaxel
  - Radiation (75 gray)

- Follow-up, 24 months later

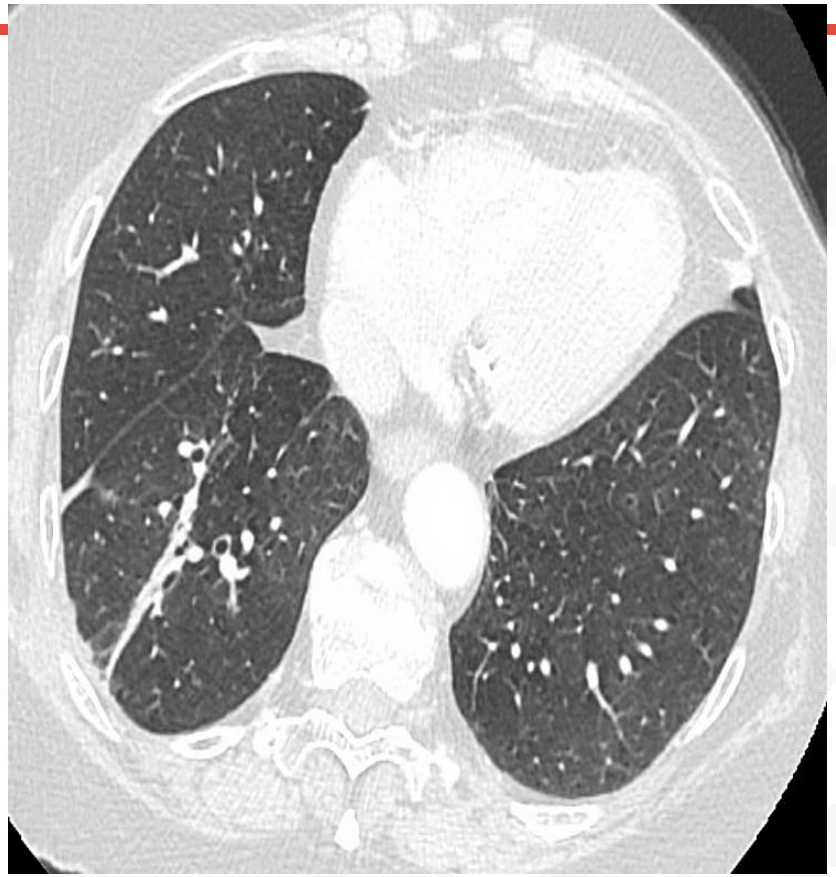

Locally advanced NSCLC

Stage III lung cancer

Type	IA1	IA2	IA3	IB	IIA	IIB	IIIA	IIIB	IIIC	IVA	IVB
Clinical	92	83	77	68	60	53	36	26	13	10	0
Pathologic	90	85	80	73	65	56	41	24	12	-	-

T/M	Label	N0	N1	N2	N3
T1	T1a ≤1	IA1	IIB	IIIA	IIIB
	T1b >1-2	IA2	IIB	IIIA	IIIB
	T1c >2-3	IA3	IIB	IIIA	IIIB
T2	T2a *Cent, Visc Pl*	IB	IIB	IIIA	IIIB
	T2a >3-4	IB	IIB	IIIA	IIIB
	T2b >4-5	IIA	IIB	IIIA	IIIB
T3	T3 >5-7	IIB	IIIA	IIIB	IIIC
	T3 *Inv*	IIB	IIIA	IIIB	IIIC
	T3 *Satell*	IIB	IIIA	IIIB	IIIC
T4	T4 >7	IIIA	IIIA	IIIB	IIIC
	T4 *Inv*	IIIA	IIIA	IIIB	IIIC
	T4 *Ipsi Nod*	IIIA	IIIA	IIIB	IIIC
M1	M1a *Contr Nod*	IVA	IVA	IVA	IVA
	M1a *Pl Dissem*	IVA	IVA	IVA	IVA
	M1b *Single*	IVA	IVA	IVA	IVA
	M1c *Multi*	IVB	IVB	IVB	IVB

Detterbeck FC, *CHEST*, 2017

Pathologic Stage (8th edition)

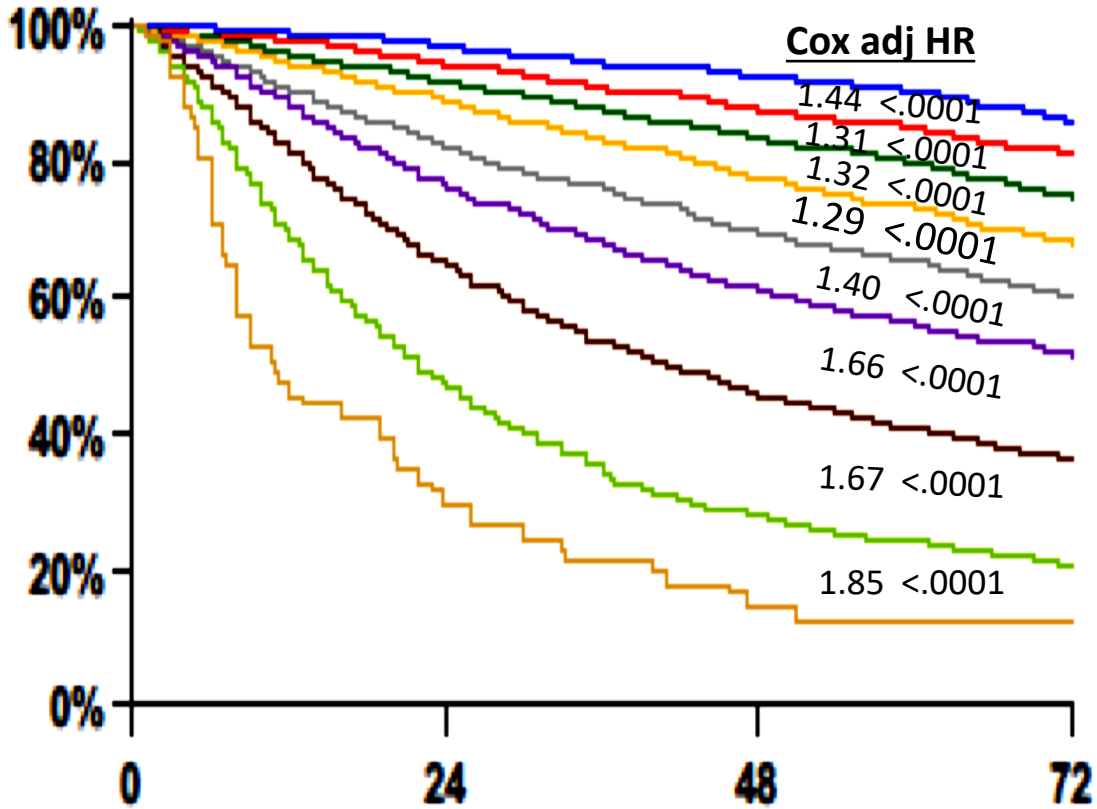

Proposed	Events / N	MST	24 Month	60 Month
IA1	139 / 1389	NR	97%	90%
IA2	823 / 5633	NR	94%	85%
IA3	875 / 4401	NR	92%	80%
IB	1618 / 6095	NR	89%	73%
IIA	556 / 1638	NR	82%	65%
IIB	2175 / 5226	NR	76%	56%
IIIA	3219 / 5756	41.9	65%	41%
IIIB	1215 / 1729	22.0	47%	24%
IIIC	55 / 69	11.0	30%	12%

Overall survival, weighted by type of database submission (registry vs other)
Cox proportional hazards adjusted for age, sex, histotype, database type

Ref: Goldstraw J Thor Oncol 2016;11:39-51

Case 2

- 77 yo F h/o DM2 and tobacco use (35 pack-years) with hemoptysis
- CT: 4.6 cm subcarinal mass
- PET: negative for disease outside the chest

- EBUS
  - Level 7 + Adenocarcinoma (KRAS)
  - Stage?

- T2bN2M0
  - IIIA

T/M	Label	N0	N1	N2	N3
T1	T1a ≤1	IA1	IIB	IIIA	IIIB
	T1b >1-2	IA2	IIB	IIIA	IIIB
	T1c >2-3	IA3	IIB	IIIA	IIIB
T2	T2a *Cent, Visc Pl*	IB	IIB	IIIA	IIIB
	T2a >3-4	IB	IIB	IIIA	IIIB
	T2b >4-5	IIA	IIB	IIIA	IIIB
T3	T3 >5-7	IIB	IIIA	IIIB	IIIC
	T3 *Inv*	IIB	IIIA	IIIB	IIIC
	T3 *Satell*	IIB	IIIA	IIIB	IIIC
T4	T4 >7	IIIA	IIIA	IIIB	IIIC
	T4 *Inv*	IIIA	IIIA	IIIB	IIIC
	T4 *Ipsi Nod*	IIIA	IIIA	IIIB	IIIC
M1	M1a *Contr Nod*	IVA	IVA	IVA	IVA
	M1a *Pl Dissem*	IVA	IVA	IVA	IVA
	M1b *Single*	IVA	IVA	IVA	IVA
	M1c *Multi*	IVB	IVB	IVB	IVB

Case 2, continued

- Not a surgical candidate
- Concurrent chemoradiation
  - Cisplatin/Pemetrexed

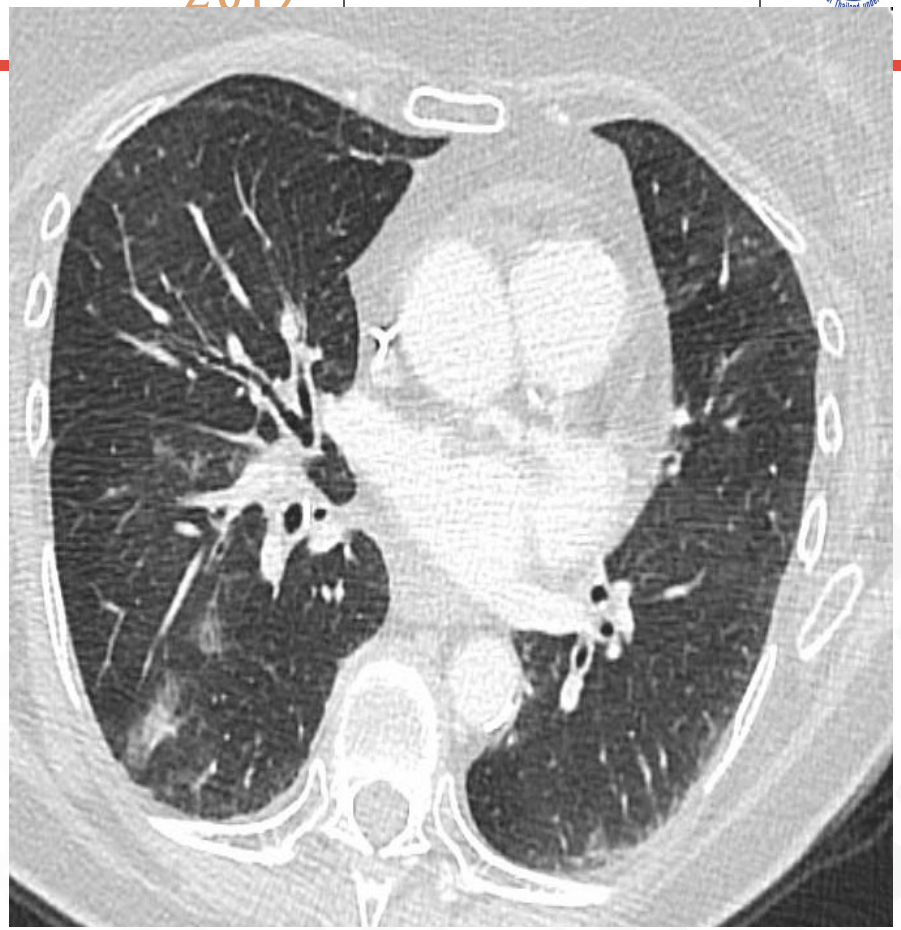

Question 1

- What further treatment recommendations for this patient?

1. no further treatment is required
2. continued chemotherapy until progression
3. adjuvant Immunotherapy
4. further treatment with chemotherapy and radiotherapy

Question 1

- What further treatment recommendations for this patient?

1. no further treatment is required
2. continued chemotherapy until progression
3. adjuvant Immunotherapy
4. further treatment with chemotherapy and radiotherapy

How does immunotherapy work?

- Signaling from dendritic cells or tumor cells can down-regulate T-cell activity
- Blockade of inhibitory signaling molecules on T-cells “re-activates” their anti-tumoral activity.

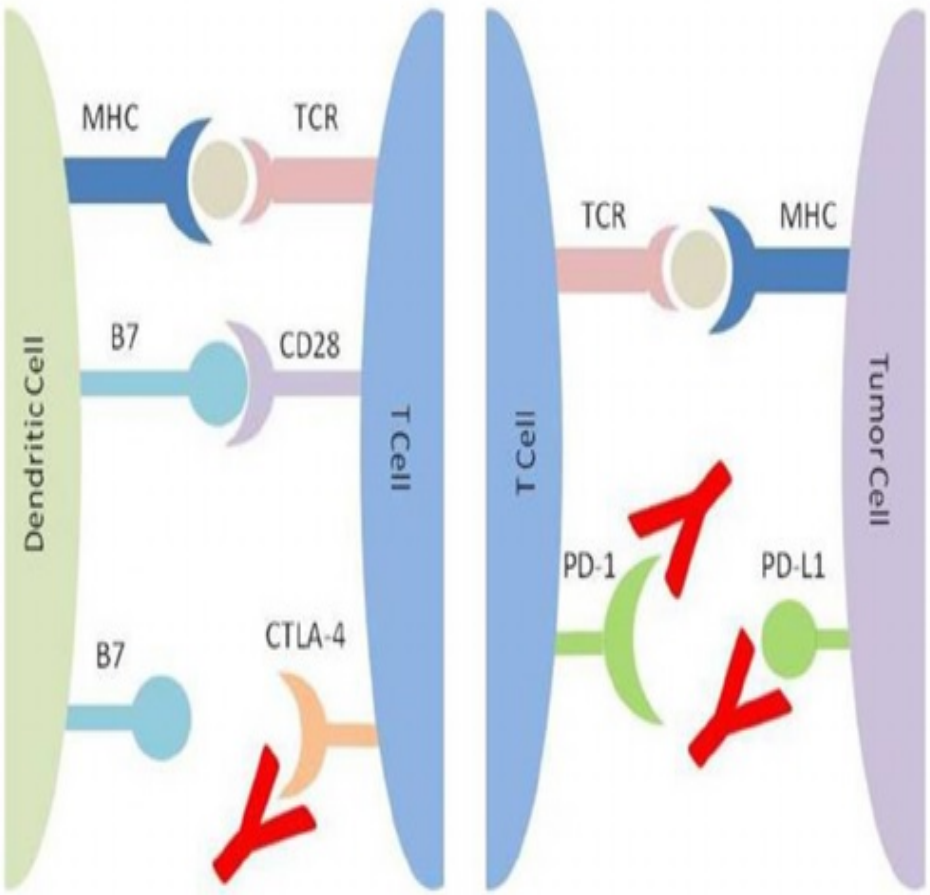

Possick JD, *Clin Chest Med*, 2017.

PACIFIC trial results

- Progression-free survival 16.8 months vs 5.6 months (HR 0.52; CI 0.42-0.65; p<0.001)

- <u>Secondary endpoints</u>
  - 12 month PFS: 55.9 vs 35.3%
  - Response rate 28.4% vs 16%
  - Ongoing response at 18 months: 72.3% vs 46.8%

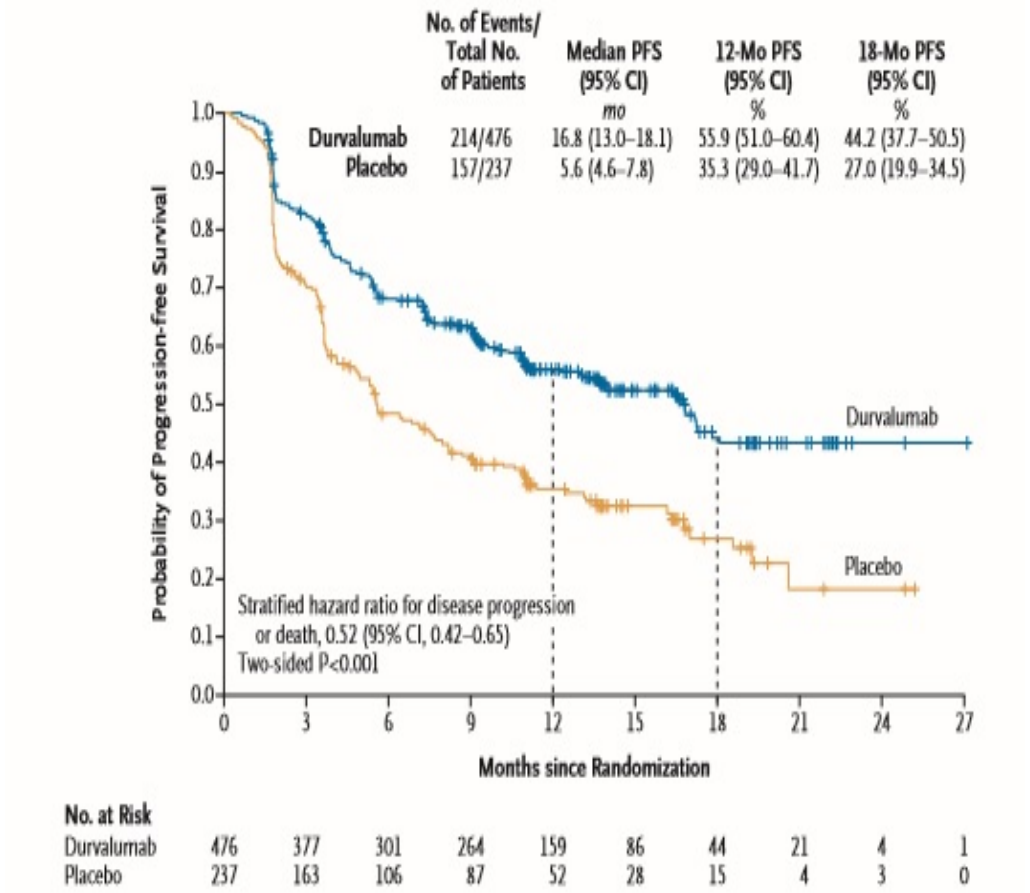

Figure 1. Progression-free Survival in the Intention-to-Treat Population.

Antonia SJ, *N Engl J Med*, 2017

Case 3: 75 year old woman with 70 pack years of smoking referred for an enlarging PET (+) mediastinal lymph node (after 6 month follow up CT). PFTs normal. No other nodules, masses, or areas of FDG uptake on PET scan.

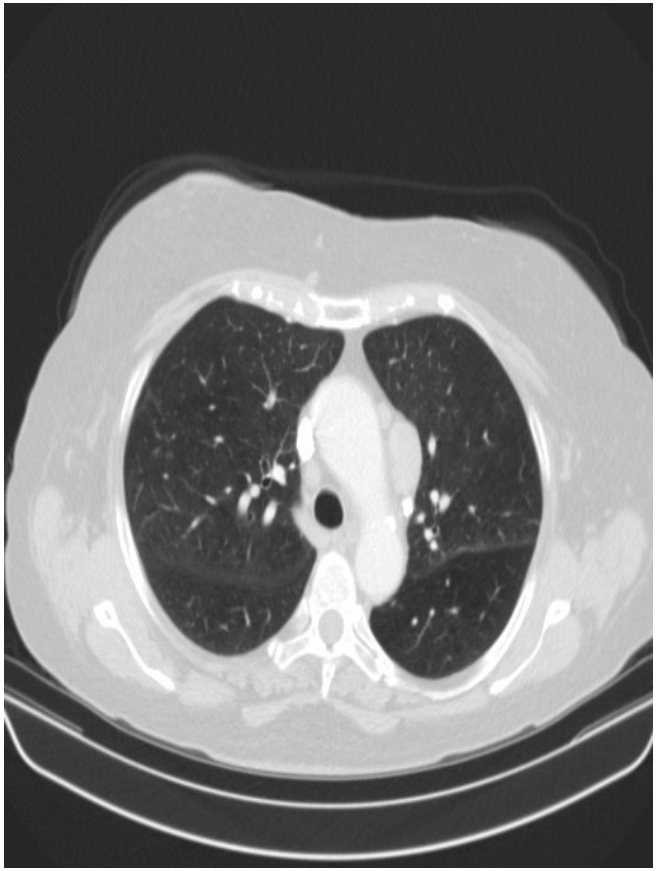

What is the best next step?

- A. EBUS TBNA for lymph node sampling
- B. Serial follow-up imaging with Chest CT scans
- C. VATS for evaluation of level 6
- D. EUS FNA for lymph node sampling

What is the best next step?

- A. EBUS TBNA for mediastinal staging
- B. Serial follow-up imaging with Chest CT scans
- C. VATS for evaluation of level 6
- D. EUS FNA for lymph node sampling

Staging at level 5 and 6

- **For the patients with a left upper lobe (LUL) cancer in whom invasive mediastinal staging is indicated, it is suggested that invasive assessment of the Aortopulmonary Window (APW) nodes be performed (via Chamberlain, VATS, or extended cervical mediastinoscopy) if other mediastinal node stations are found to be uninvolved**
- (Grade 2B).

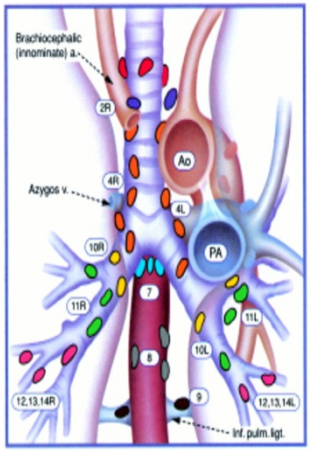

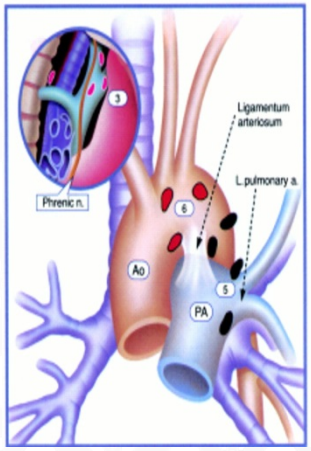

Superior mediastinal nodes
- 1 Highest mediastinal
- 2 Upper paratracheal
- 3 Prevascular and retrotracheal
- 4 Lower paratracheal (including azygos nodes)

N2 = single digit, ipsilateral
N3 = single digit, contralateral or supraclavicular

Aortic nodes
- 5 Subaortic (A-P window)
- 6 Para-aortic (ascending aorta or phrenic)

Inferior mediastinal nodes
- 7 Subcarinal
- 8 Para-oesophageal (below carina)
- 9 Pulmonary ligament

N1 nodes
- 10 Hilar
- 11 Interlobar
- 12 Lobar
- 13 Segmental
- 14 Subsegmental

Silvestri et al. Chest 2013. 143(5): e211S–e250S

Mountain, et al. Chest 1997; 111:1718-23

Case 1 continued: VATS performed

- Nodule in the left upper lobe seen and palpated (not appreciated on imaging)
- Wedge resection performed: frozen section NSLC
- Level 6: tumor deposit 2.5cm
- Total 1/26 lymph nodes (+)
- Lobectomy completed

Are all N2 nodes created equal?

- Nonrandomized evidence that involvement of a single, left level 5 mediastinal lymph node in patients with a left upper lobe tumor portends no worse of a prognosis than N1 disease.
- Median survival was 51.4 months (95% CI, 22.3 months–not reached) for patients with left upper lobe tumors and single-level N2 metastases and 49.4 months (95% CI, 25.4-89 months) for patients with left upper lobe tumors and N1 disease; 5-year survival was 42% in both groups.

Patterson GA, et al. Ann Thorac Surg 1987;43:155–159.
Keller SM, et al. J Thorac Cardiovasc Surg 2004;128:130–137
Cerfolio RJ, et al. ***Ann Thorac Surg 2008; 86: 912–920.***

Left upper lobe tumors and single-level N2 metastases vs. N1 disease

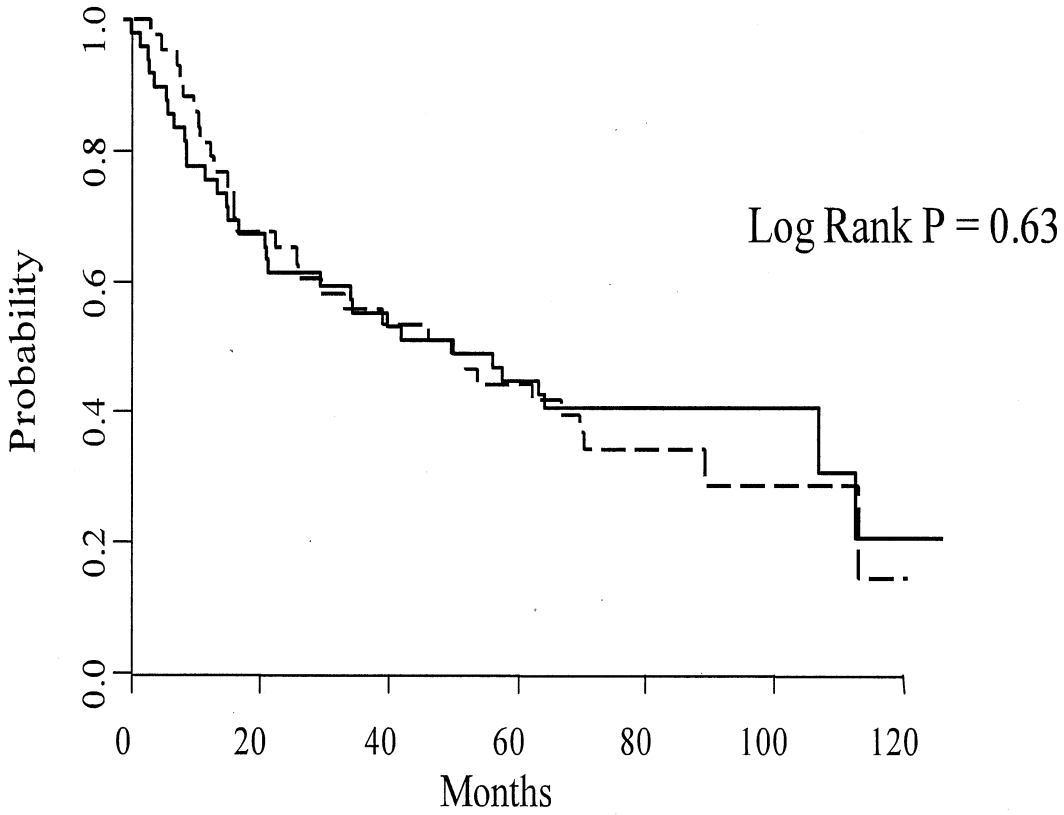

		Total	Dead	Median Survival
———	N1	43	30	49.4 months
- - - - -	N2	49	31	51.4 months

Keller SM, et al. J Thorac Cardiovasc Surg 2004;128:130–137

N2 disease

- **In patients with discrete N2 involvement by NSCLC identified preoperatively (IIIA), we recommend the treatment plan should be made with the input from a multidisciplinary team (Grade 1C)**

- **In patients with NSCLC who have incidental (occult) N2 disease (IIIA) found at surgical resection despite thorough preoperative staging and in whom complete resection of the lymph nodes and primary tumor is technically possible, completion of the planned lung resection and mediastinal lymphadenectomy is suggested (Grade 2C)**

Pancoast tumor

- Less than 5% of lung cancers
- Cancer in the superior sulcus
- Destructive lesions of the thoracic inlet
- Involvement of the brachial plexus and cervical sympathetic nerves (stellate ganglion)
- Mostly extrathoracic, involving the chest wall structures

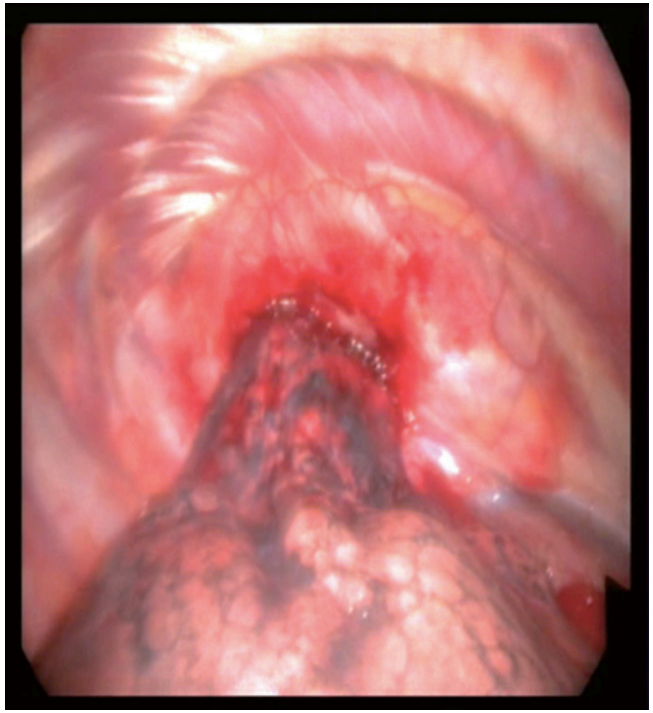

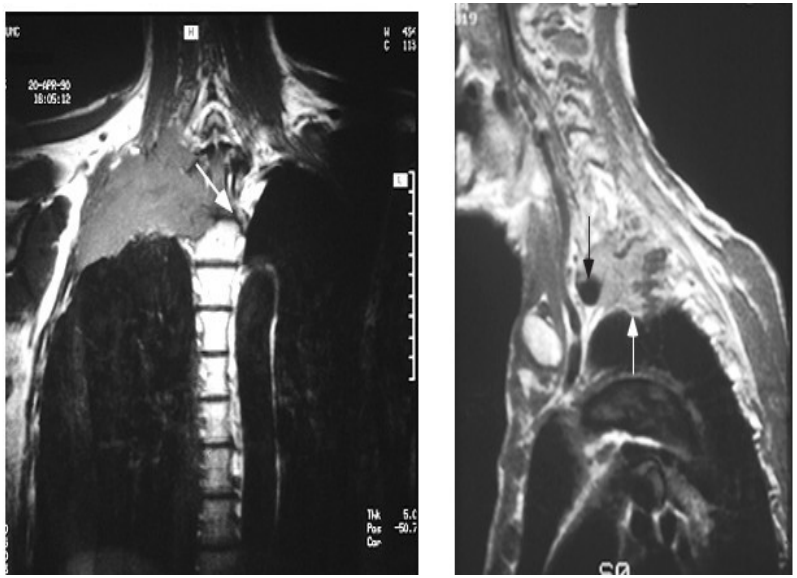

Pancoast HK. *JAMA*. 1924. 83:1407-1411.
Pancoast HK. *JAMA*. 1932. 99:1391-1396.

Foroulis et al. Journal of Thoracic Disease 20

Symptoms

- Severe pain in the shoulder region radiating toward the axilla and scapula, with later extension along the ulnar aspect of the arm to the hand
- Atrophy of hand and arm muscles
- Horner syndrome (ptosis, miosis, hemianhydrosis, enophthalmos)
- Compression of the blood vessels with edema

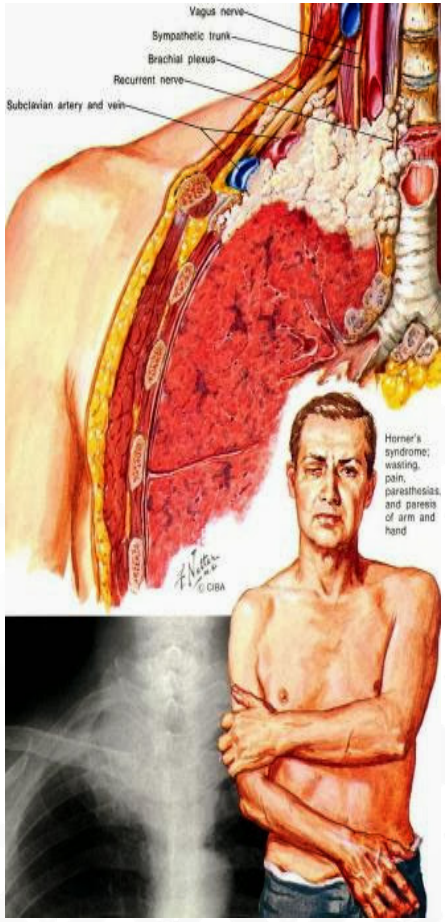

Pancoast HK. *JAMA*. 1924. 83:1407-1411.
Pancoast HK. *JAMA*. 1932. 99:1391-1396.

Question 3

In a patient with a Pancoast tumor the recommended treatment regimen should include?

1. chemotherapy with radiation therapy
2. Surgery followed by radiation
3 induction chemotherapy and radiotherapy followed by surgery
4. Radiation followed by surgery

Question 2

In a patient with a Pancoast tumor the recommended treatment regimen should include?

1. chemotherapy with radiation therapy
2. Surgery followed by radiation
3 Induction chemotherapy and radiotherapy followed by surgery
4. Radiation followed by surgery

Treatment

- Induction chemo-radiotherapy is the standard of care for any potentially resectable Pancoast tumor
- Complete tumor resection
- Anterior and posterior approaches to the thoracic inlet depending on location of the tumor (posterior - middle - anterior compartment of the thoracic inlet) and the depth/extent of invasion.

Peedell C, et al. Clin Oncol (R Coll Radiol) 2010;22:334-46.
Pitz CC, et al. Eur J Cardiothorac Surg 2004;26:202-8.
Detterbeck FC, Et Ann Thorac Surg 2003;75:1990-7.

Unresectability

- Distant metastases, including a single brain metastasis
- Ipsilateral or contralateral mediastinal or supraclavicular nodes (N2/N3 disease)
- Involvement of the brachial plexus above the T1 (weakness of the intrinsic muscles of the hand is expected by sacrificing only the T1 nerve root, while sacrificing the C1 nerve root produces a permanent paralysis and severe disability of the dependent upper extremity)
- Involvement of more than 50% of the vertebral bodies;
- Invasion of the esophagus and/or trachea.

Tamura M, et al. Eur J Cardiothorac Surg 2009;36:747-53.
Rusch VW, et al. Lancet Oncol 2006;7:997-1005.
Dartevelle P, et al. Acta Chir Austriaca 1999;31:270-4.

Prognosis

- Surgery associated with 5% mortality rate
- Complication rate varies from 7-38%.
- The overall 2-year survival rate after induction chemo-radiotherapy and resection varies from 55% to 70%, while the 5-year survival for R0 resections is quite good (54-77%). The main pattern of recurrence is that of distant metastases, especially in the brain.

Peedell C, et al. Clin Oncol (R Coll Radiol) 2010;22:334-46.
Pitz CC, et al. Eur J Cardiothorac Surg 2004;26:202-8.
Archie VC, et al. Oncologist 2004;9:550-5.

Summary

- Standard of care for most patients with IIIA NSCLC is chemoradiotherapy
- For select cases where patients with stage IIIA NSCLC are surgical candidates, a tumor board discussion is warranted weighing patient preferences, risks, and benefits of neoadjuvant chemoradiotherapy followed by surgery.
- Involvement of a single A-P window lymph node in patients with a left upper lobe tumor may portend a better prognosis than in other cases of stage IIIA disease.
- Tumor size has more prognostic impact than previously recognized, and a tumor > 7 cm is considered T4.
- Adjuvant Immunotherapy is now considered after definitive treatment
- Induction chemo-radiotherapy should be standard of care for any potentially resectable Pancoast tumor