CHEST® Live Learning

Update on Bronchoscopy and Interventional Pulmonary Procedures

Nicholas J. Pastis MD, FCCP

Professor of Medicine

Division of Pulmonary & Critical Care

Medical University of South Carolina, USA

Disclosures

- Consultative work and research support from Olympus
- Research support from Auris
- Research support from Veran
- Consultative work from Boston Scientific

Objectives

- An update on the various ablative modalities
- An update on tracheal and bronchial stents
- Bronchoscopic treatment options for lung volume reduction in emphysema and for persistent air leaks

Case 1: 64 yo woman previous left pneumonectomy for adeno of the lung with shortness of breath, wheezing, and unable to lie flat.

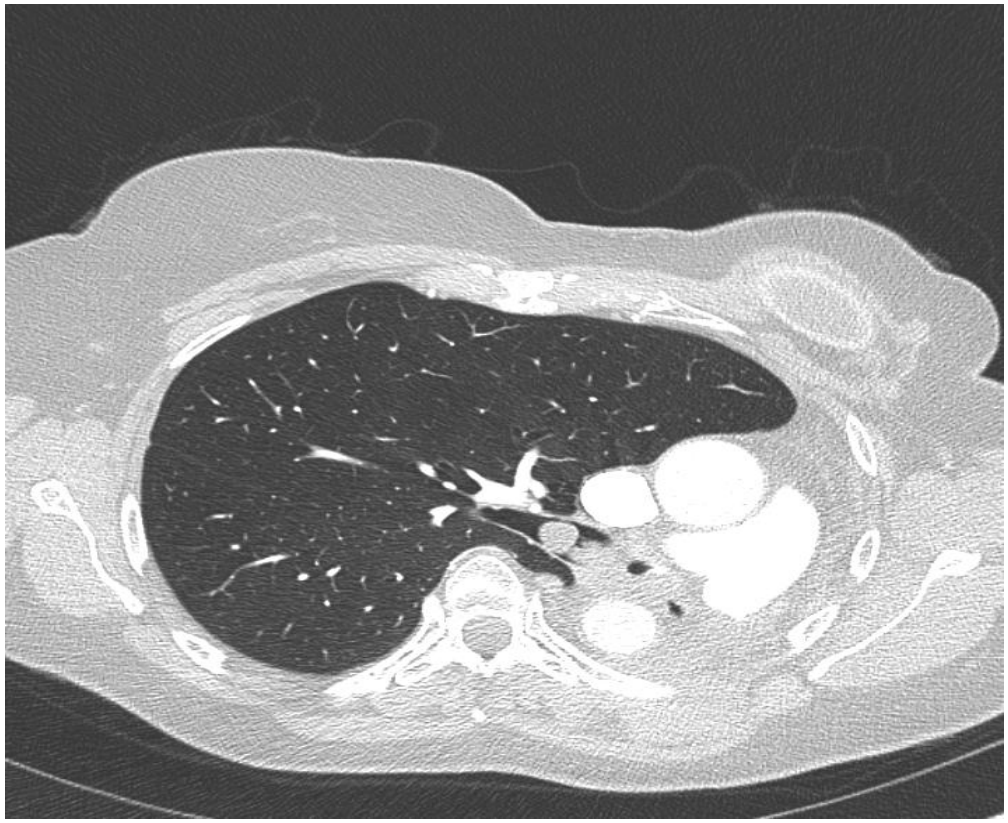

Which of the following is the best next best step?

A. Immediately transition to comfort care only

B. Place a stent inside the small opening in the RMS bronchus

C. Rigid bronchoscopy with electrocautery snare

D. Endotracheal tube intubation

Case 1…

CHEST® Live Learning

RMS Bronchus Before

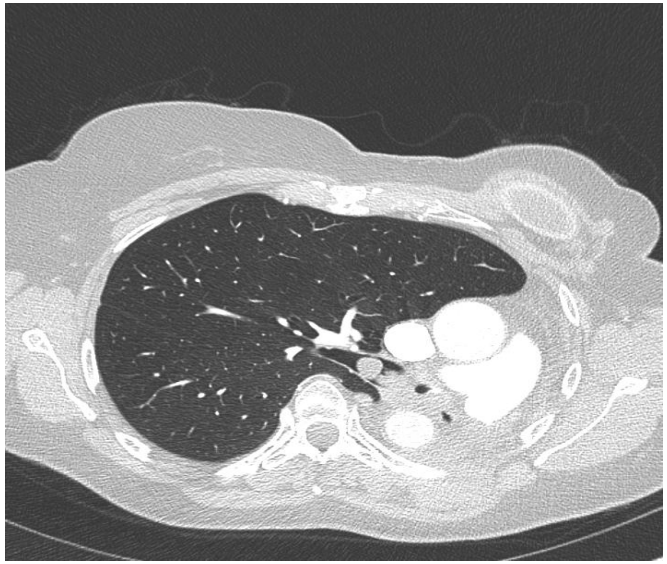

RMS Bronchus after electrocautery snare, stalk should be cauterized (path. positive for recurrence)

Malignant CAO

- CA typically refers to trachea, RMS, LMS, and BI.
- 20-30% of lung cancer patients develop airway obstruction
- DOE when tracheal diameter < 8 mm
- Dyspnea at rest when < 5mm

Ginsberg et al. *Cancer Principles and Practice of Oncology*. 858-911
Hollingsworth. Clin Chest Med 1987;8:231-40
Geffin. JAMA 1971; 216:1984-8

Types of malignant CAO

- Bronchogenic carcinomas
- Metastatic lesions
- Direct invasion

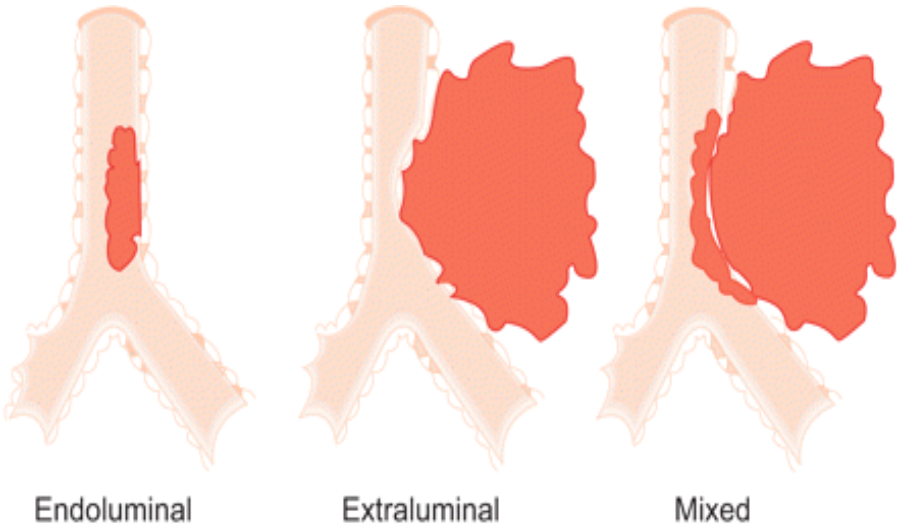

Bolliger et al. ERJ 2006: 27(6) 1258-1271.

Evaluation

- Physical exam, imaging and flow-volume loop

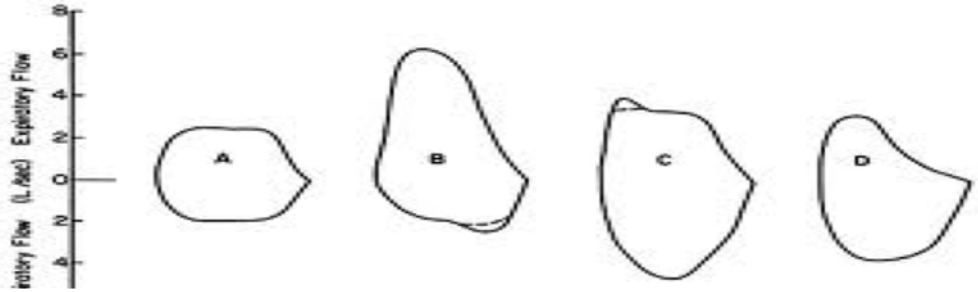

- Bronchoscopy is the “gold standard”
  - Diagnosis
  - Measurements
  - Guidance of therapy

- Is emergent endotracheal intubation needed?

Kvale et al. Chest 2007; 132;368S-403S

Rigid bronchoscopy

Type	Advantages	Disadvantages
Rigid	-Comfort -More tools -Scope can dilate, core, and use rigid forceps -Equipped for serious complications -Provides an airway for ventilation	-Requires anesthesiology support -Extra training -Small percentage of pulmonologists use (4% in one survey Colt et al. *J Bronchol.* 2000;7:8)
Flexible	-Available to all pulmonologists -Does not require anesthesiology support -Less expensive	-Longer procedures -May require > 1 session -Less ability to resect and cannot compress -Flammable instruments -Not well suited for serious complications like bleeding or loss of airway

Laser

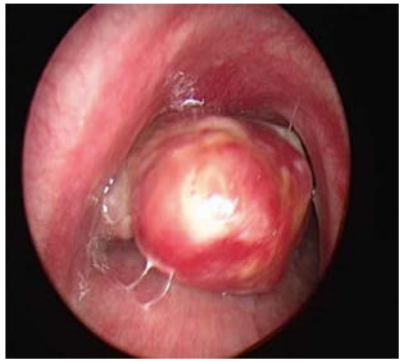

- CO_2, KTP, Nd:YAG, YAP, Argon, and Diode laser
- Results equivalent to thermo-coagulation but laser may shorten procedure (not been prospectively compared).

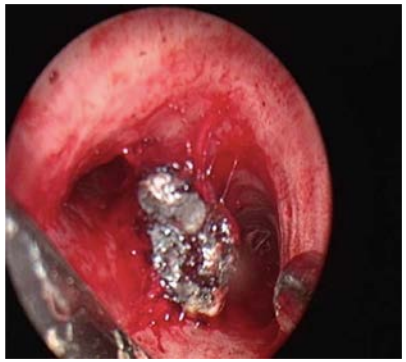

- Risk of airway fire > 0.4 FiO_2 level
- Risk of perforation of the tracheobronchial wall to cause a vascular fistula, gas embolism, and/or mediastinitis avoided by respecting a tangential axis and a non-contact treatment (1 cm).

Guibert et al. J Thorac Dis 2016;8(11):3343-3360

Electrocautery

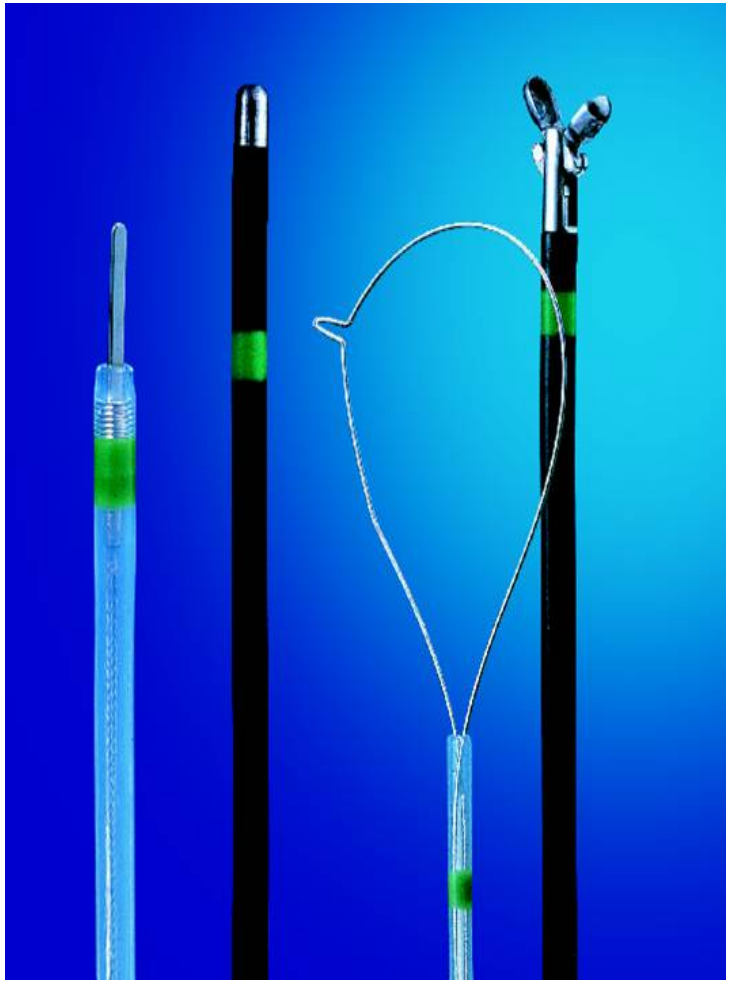

- Direct contact conducts electricity, thermal energy
- Less risk of distal airway perforation, lower cost, variety of probes/snare
- Tissue contact requires cleaning

Ross et al. Current Opinion in Anaesthesiology 2009, 22:11-17

Argon Plasma Coagulation

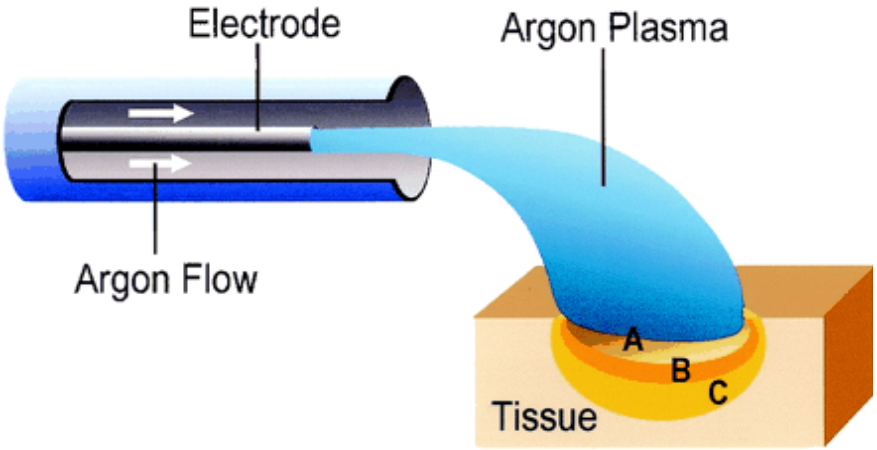

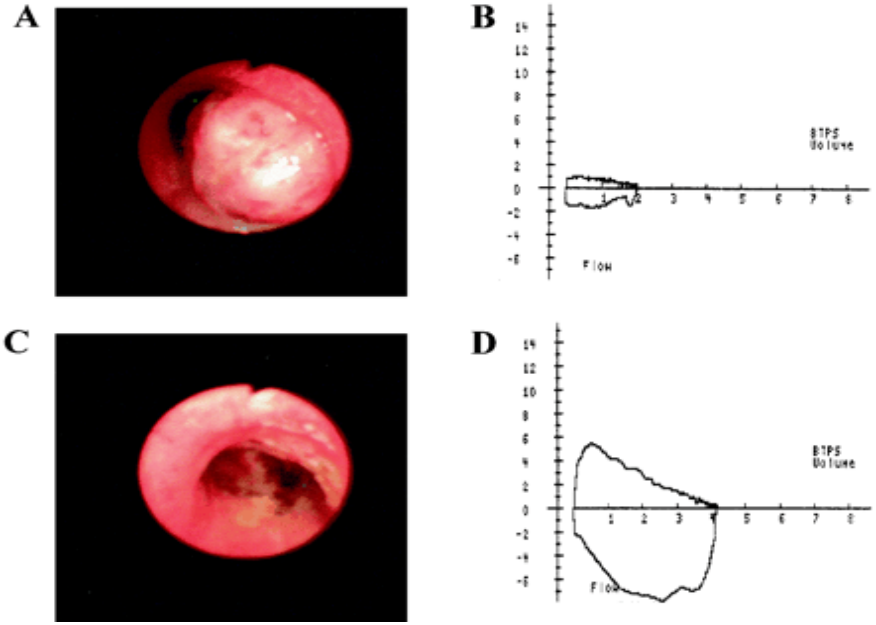

- Ionized argon gas flow **conducts** electricity to tissue, non-contact
- Necrosis 2-3mm; coagulation; around bends
- Time consuming for significant tumor debulking

Ross et al. Current Opinion in Anaesthesiology 2009;22:11-17

Morice et al. Chest, 2001; 119(3): 781-787

Photodynamic Therapy (PDT) for Microinvasive NSCLC (Stage 0) or Obstructing NSCLC

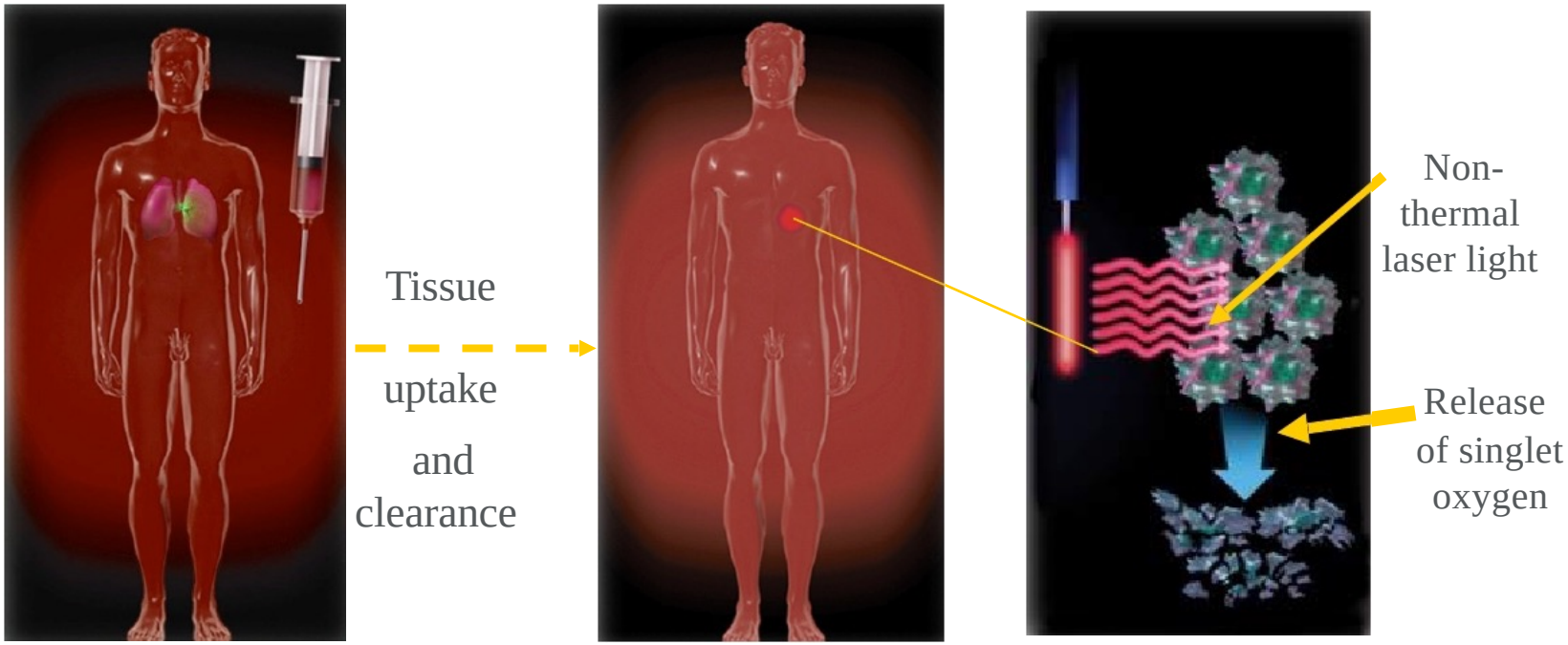

Photosensitizing Agent (IV Administration)

Relatively Selective Retention in Tumor

Tumor Tissue Destruction

NCCN NSCLC Guidelines

National Comprehensive Cancer Network®

NCCN Guidelines Version 3.2017
Non-Small Cell Lung Cancer

THERAPY FOR RECURRENCE AND METASTASIS

Locoregional recurrence

- Endobronchial obstruction → Any combination of the following:
  - Laser/stent/other surgery[k]
  - External-beam RT or brachytherapy[l]
  - Photodynamic therapy
- Resectable recurrence → Any combination of the following:
  - Reresection (preferred)[k]
  - External-beam RT or SABR[l,m]
- Mediastinal lymph node recurrence
  - No prior RT → Concurrent chemoradiation[l,q]
  - Prior RT → Systemic therapy (NSCL-17)
- Superior vena cava (SVC) obstruction → Any combination of the following:
  - Concurrent chemoradiation[l,q] (if not previously given)
  - External-beam RT[l]
  - SVC stent
- Severe hemoptysis → Any combination of the following:
  - External-beam RT or brachytherapy[l]
  - Laser or photodynamic therapy or embolization
  - Surgery

→ Chest CT with contrast
→ Brain MRI with contrast
→ PET/CT

Microdebrider

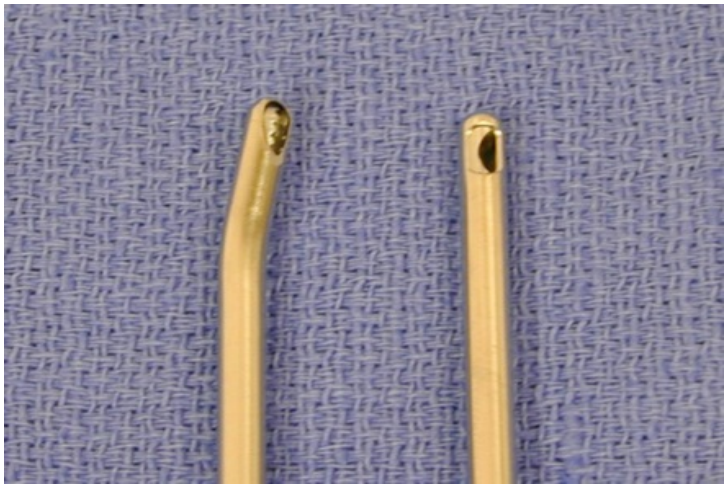

- High speed rotational cutting blades
- Built-in suction to remove debris; no risk of fire
- Distal lesions require extended length
- Needs separate hemostasis modality

Cryotherapy

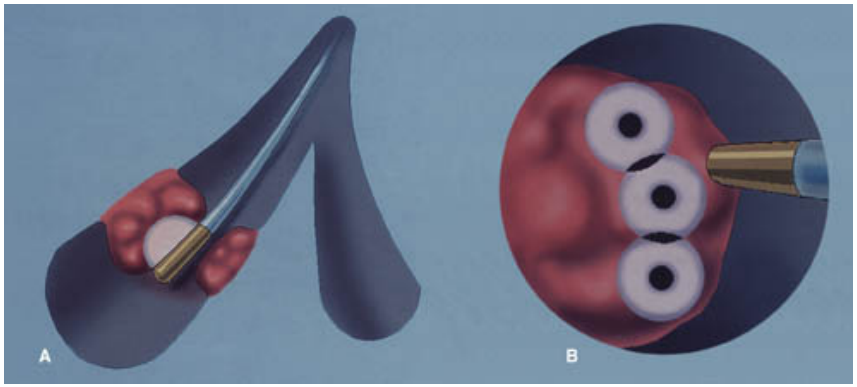

- Repetitive tissue freezing and thawing cycles from N2O expansion
- Cartilage resists freezing; complications rare, no risk of airway fire
- Delayed effects; follow up bronchoscopy; not for urgent airway

Cryo recanalization

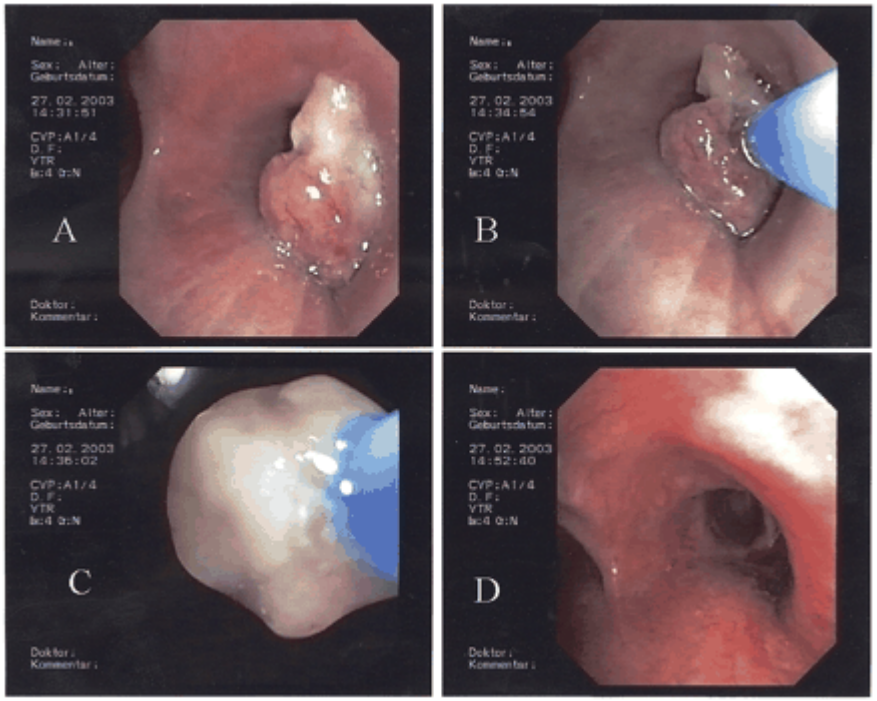

Hetzel et al. J Thorac Cardiovasc Surg 2004; 127(5): 1427-31

Cryospray Ablation

- Non-contact method of cryotherapy using low-pressure liquid nitrogen spray
- Even, linear distribution of cryogen over larger area
- 2-4 cycles of 5 second spray
- followed by 60 second thaw
- Must adequately vent liquid nitrogen or risk barotrauma

Fernando HC, et al. Eur J Cardiothorac Surg 2011; 40:1177-1180
Lackner RP, Trujillo KP. Chest 2010; 138:424A

Case 2

- 42 year old male with extensive SCLC (R adrenal)
- Scheduled for but hasn't received 1st cycle of Cis-Etoposide; has worsened cough and dyspnea
- What to recommend when consulted for a stent?
  A. Stent RUL segments
  B. Laser treatment RUL
  C. Chemotherapy
  D. Comfort care only

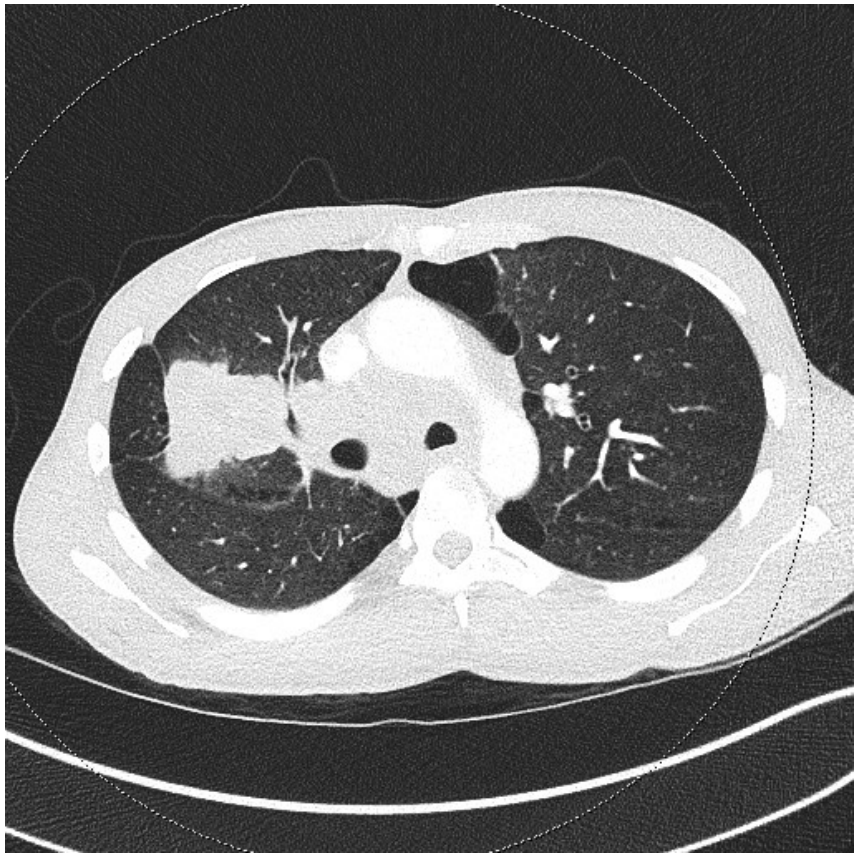

Case 2…

- Stent not placed
- Chemotherapy with cisplatin and etoposide
- Resumed chemo after pneumonia resolved

Case 3

65 year old with severe respiratory papillomatosis (distant right lower lobectomy) now with recurrent hospitalizations for LLL pneumonias. Multiple Bronchs with electrocautery to treat disease obstructing left lower lobe bronchus and CT shows a left hilar mass (blue arrow). Biopsies now show squamous cell carcinoma.

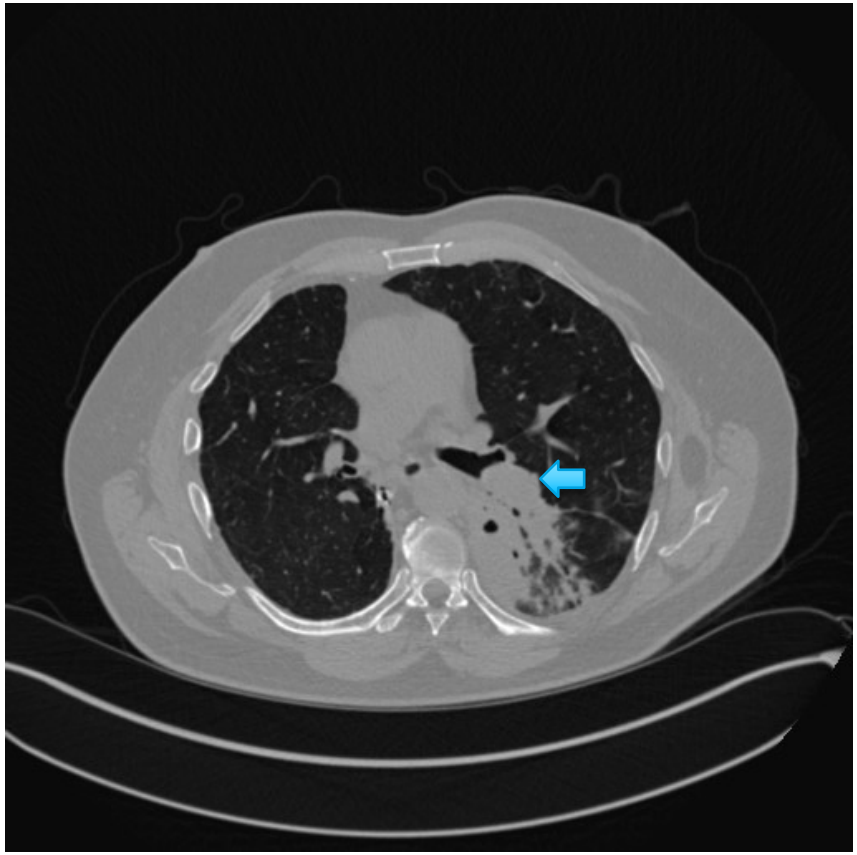

LC2 before

LC2 after APC, external beam radiation and placement of a 6mm x 16mm I-Cast stent

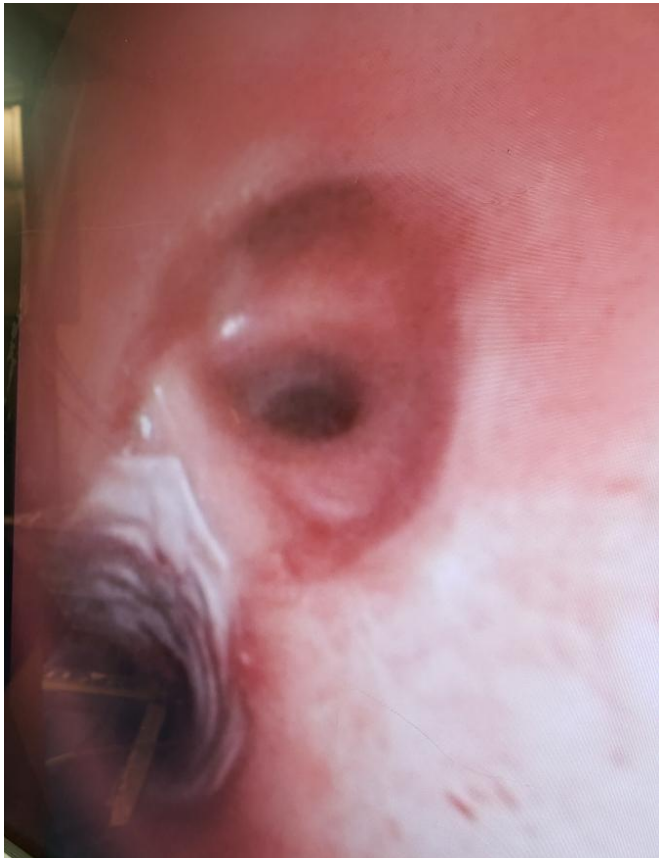

To stent or not stent segmental airways for “lobar salvage”?

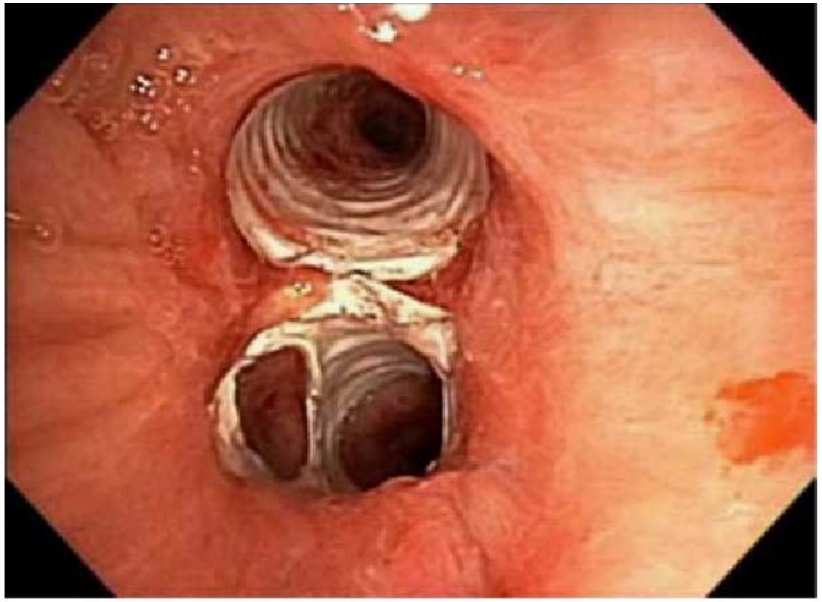

Sethi et al. J Bronchology Interv Pulmonol 2018 Jan;25(1):9-16

Case 4

- 64 yo male with shortness of breath and stridor
- Tracheal mass found on PE study in ED
- On FiO2 3L/min, pH 7.29, pCO2 58, pO2 85; repeat after nebulizer and coughing mucous plug was pH 7.38, pCO2 45, pO2 69
- Transferred to ICU on heliox/oxygen

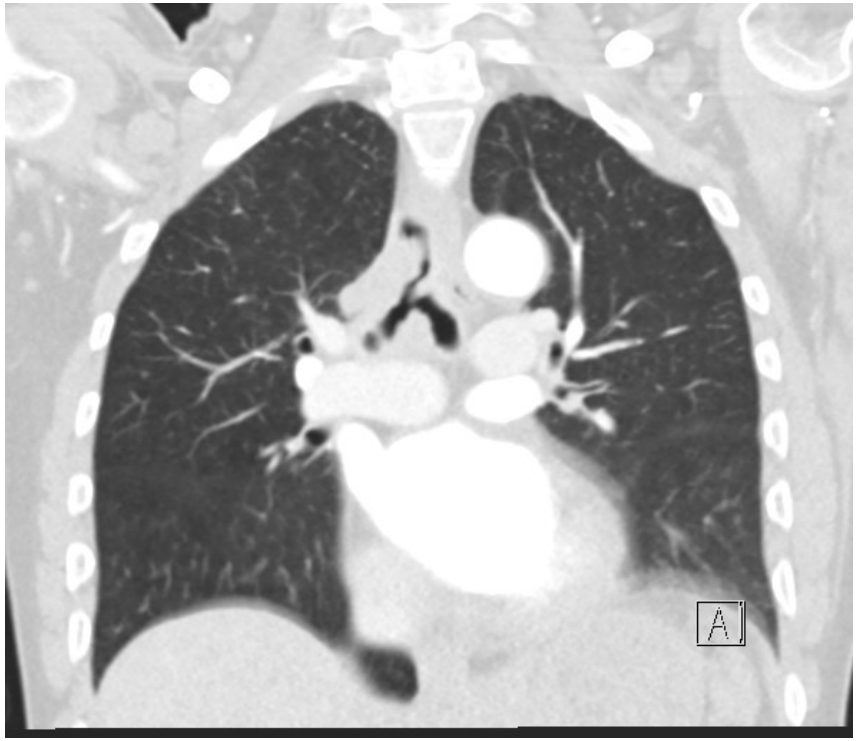

What would you recommend next when patient arrives to ICU?

- A. Endotracheal intubation
- B. Flexible bronch to obtain a diagnosis and then start emergent XRT
- C. Rigid bronchoscopy
- D. Surgical resection of mass

Urgent rigid bronch used bevel and rigid forceps to core

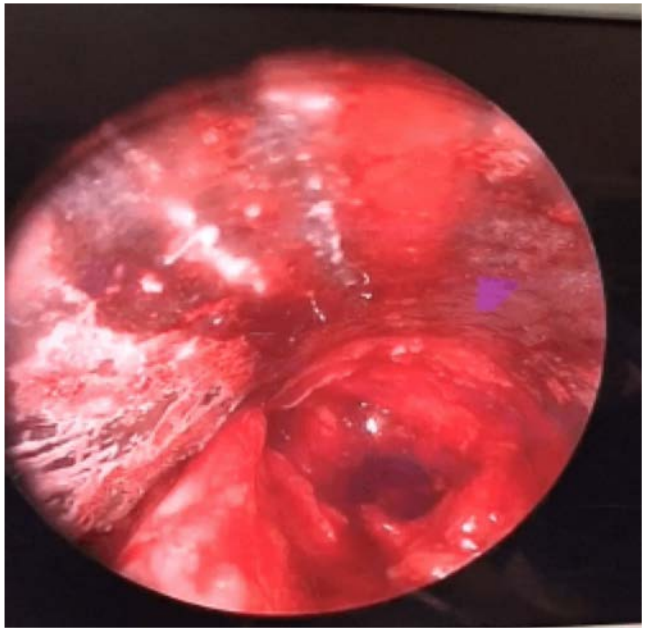

Placed covered SEM stent

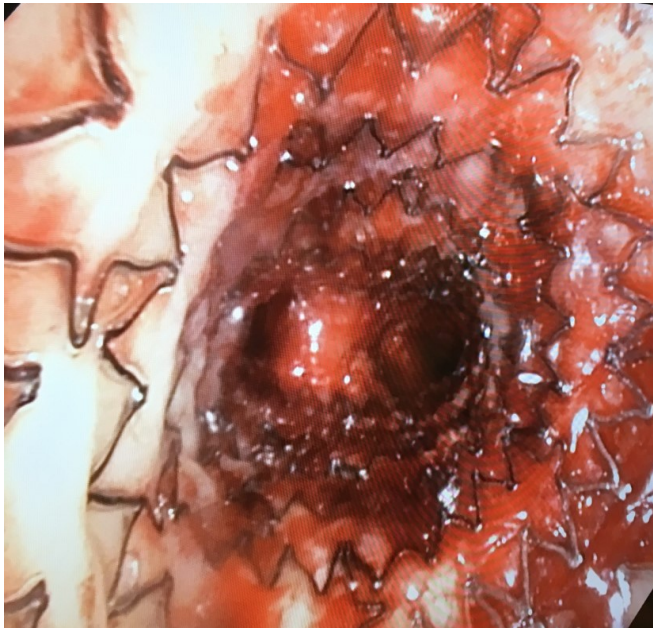

Case 4 cont...

- Biopsies from rigid forceps returned as squamous cell carcinoma.
- Dyspnea and stridor resolved; patient ambulatory.
- Patient discharged for outpatient PET scan, brain MRI, and consultation with med onc and rad onc.

Bronchoscopic Intervention Obviates the Need for Continued Mechanical Ventilation in Patients with Airway Obstruction and Respiratory Failure from Inoperable Non-Small-Cell Lung Cancer

- 12 consecutive intubated and mechanically ventilated patients with inoperable or unresectable CAO from NSCLC
- Airway patency restored in 11/12 patients (91%)
- Bronchoscopic intervention resulted in immediate extubation and discontinuation of mechanical ventilation in 9/12 (75%) of patients.
- Overall median survival was 228 days (range 6-927).
- For the 9 patients extubated within 24 hours after intervention, however, median survival was 313 days (range 6-927).

Murgu et al. Respiration 2012;84: 55-61.

Case 5

- 57 yo female with ESRD, DM, COPD, and CHF presents with subglottic stenosis.
- Hospitalized 5 months ago for respiratory failure requiring intubation and a tracheostomy.
- She was decannulated 2 months later.
- A recent CT showed a narrowing at the cervicothoracic trachea.
- Now presents with acute respiratory failure.

Intubation with 5.5 ETT

Which of the following is the best option to manage this complex bilevel subglottic stenosis (stricture above cricoid level and severe malacia at prior trach site) now that the patient is intubated?

- A. Place a SEM sized for trachea just below the cords.
- B. Make radial cuts of fixed stenosis and then dilate fixed stenosis along with area of malacia at prior trach site.
- C. Rigid bronch with dilation of stenosis and then silicone stent placement to cover malacia.

Had subglottic stenosis but bigger problem **malacia at prior tracheostomy site (this is exp collapse)**

Dilated stenosis and placed 16 x 5 dumbbell shaped silicone stent

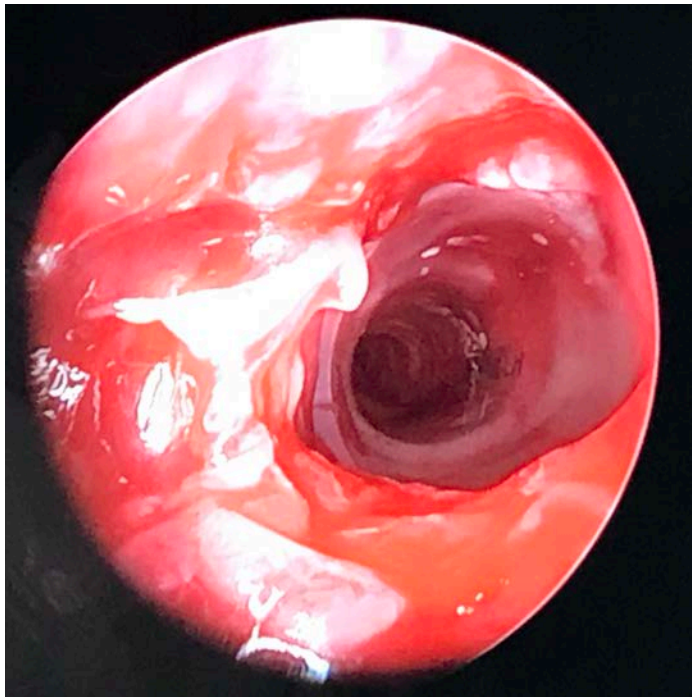

Silicone stent options

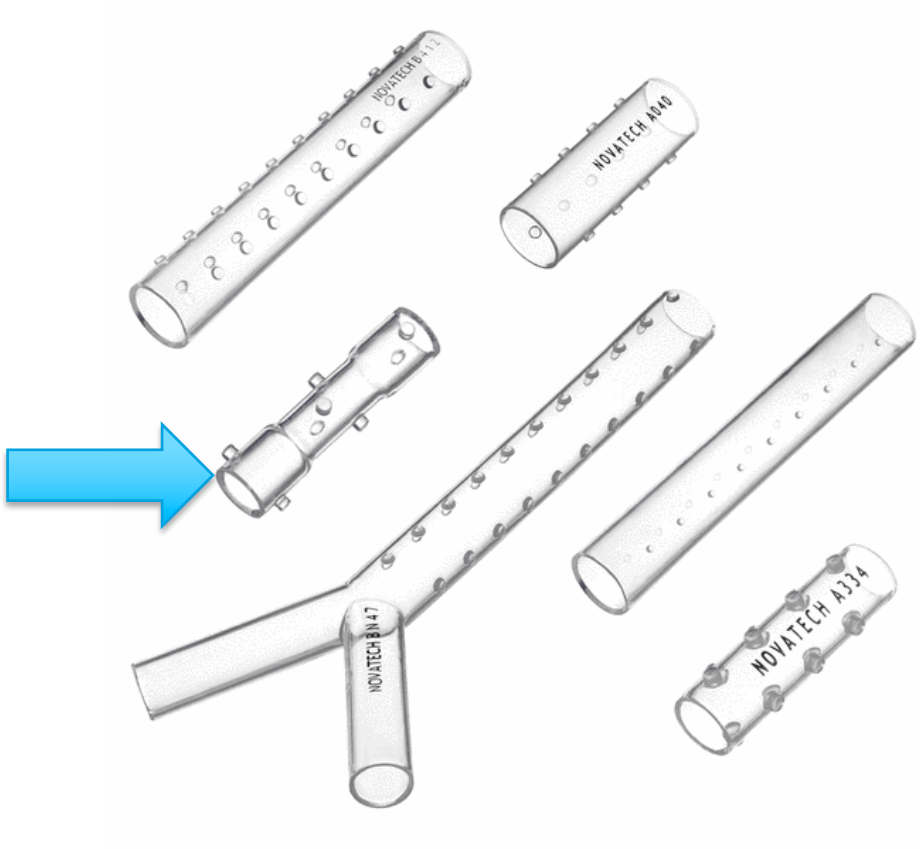

CHEST® Live Learning

Endobronchial Valves for Lung Volume Reduction in Severe Emphysema

Clinical Consequences of Hyperinflation In Emphysema

- Increased Breathlessness
- Impaired Respiratory Muscle and Chest Wall Mechanics
- Decreased Exercise Performance
- Decreased Quality of Life
- Prolonged Respiratory Failure Requiring Mechanical Ventilation
- Increased Mortality (IC/TLC)

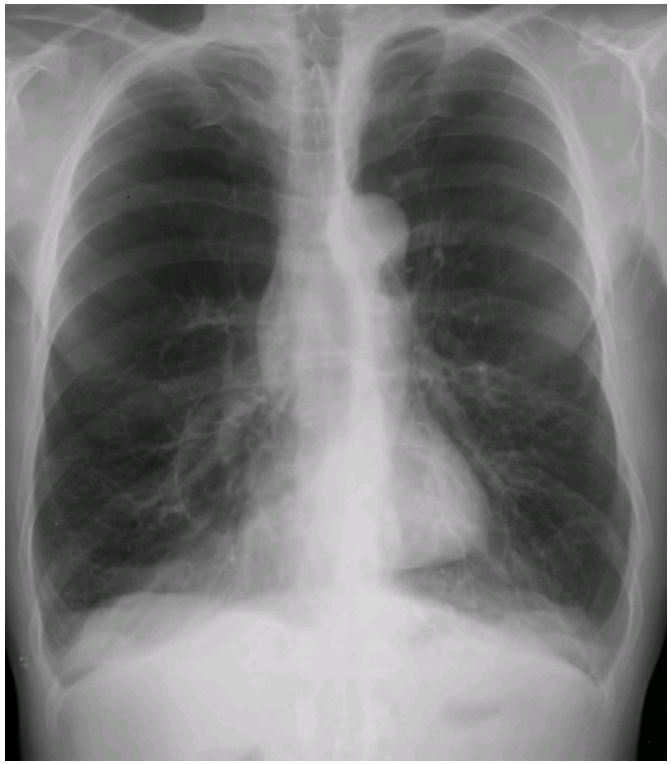

LVRS Treats Hyperinflation (NETT)

- Benefits
  - Improves long-term survival (median follow-up 4.3 years)
  - Improves lung function, exercise performance and quality of life
  - Decreases frequency of exacerbations
- Negative Aspects
  - Associated mortality
  - Pulmonary and cardiac morbidity
  - Does not help all patients
  - Limited access
  - Costly

NETT Research Group, NEJM, 2003; Naunheim, Ann Thor Surg 2006; Naunheim, JTCVS, 2006; Criner AJRCCM, 2011

Bronchoscopic Lung Volume Reduction

Targeted Lobe Atelectasis

- One–way endobronchial valves
- Self-activating coils

Targeted Destruction & Remodeling of Emphysematous Tissue

- Biological Lung Volume Reduction
- Bronchoscopic Thermal Vapour Ablation (BTVA)

Bypass Tract Stenting/Transpleural Ventilation

- Endobronchial stents
- Modified external chest tubes

Bronchial Valve Therapy Concept

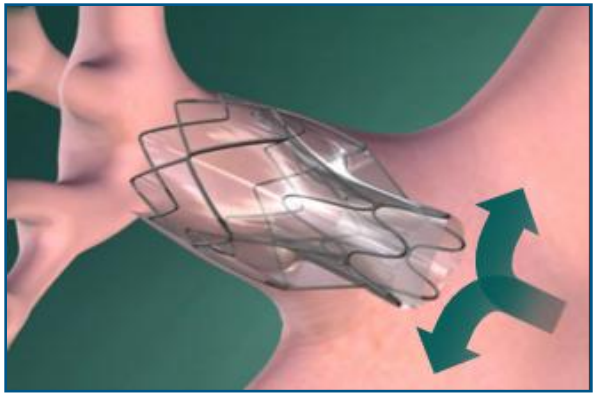

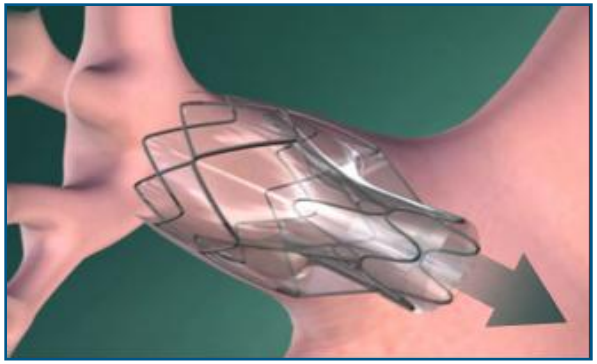

Uni-directional valve implanted in airway

- Lobar exclusion via valve implantation in all airways supplying target lobe
- Silicone coated, self-expanding scaffold ensures tight seal in airway
- Valve allows trapped air and fluids to escape

Endobronchial Valves for BLVR

Zephyr and SVS Endobronchial Valves are FDA approved for BLVR

CLINICAL TRIALS

LIBERATE
TRANSFORM
IMPACT
STELVIO

CLINICAL TRIALS

REACH
EMPROVE

Indications

Pulmonx Zephyr® Endobronchial Valves are implantable bronchial valves indicated for the bronchoscopic treatment of adult patients with hyperinflation associated with severe emphysema in regions of the lung that have little to no collateral ventilation.

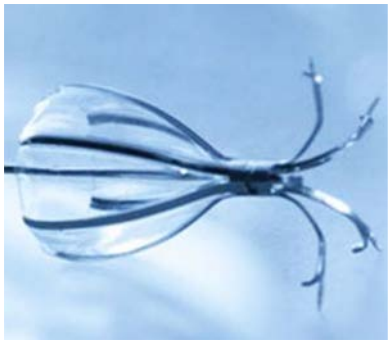

Spiration Valves are one-way endobronchial valves indicated for adult patients with shortness of breath and hyperinflation associated with severe emphysema in regions of the lung that have evidence of low collateral ventilation.

Inclusions

- Diagnosis of emphysema confirmed by CT
- BMI < 35 kg/m2
- Stable with ≤ 20mg prednisone daily
- Residual volume ≥ 175% predicted (≥ 200% if homogeneous)
- FEV_1 15-45% predicted
- TLC ≥ 100% predicted
- 6MWD 100-500m (150-500m if homogeneous)
- Not actively smoking (for at least 4 months)
- Target lobe with little or no collateral ventilation (as measured by Stratx and/or Chartis Assessment

- 40 yrs. old
- Severe emphysema
- Stable COPD ≥ 6 weeks
- FEV_1 ≤ 45% pred.
- RV≥ 1505 pred.
- TLC≥ 1005 pred.
- 6MWD ≥ 140M
- Target lobe ≥ 40 % emphysema
- Fissure integrity≥ 90%

Exclusions

- Bronchoscopic procedures are contraindicated
- Active pulmonary infection
- Allergies to Nitinol, Nickel, Titanium, or Silicone
- Still smoking
- Large bullae encompassing >30% of either lung
- UNABLE to complete preoperative and postoperative pulmonary programs required for the procedure.
- Severe hypercapnia ($PaCO_2$ ≥50 mm Hg on room air) and/or severe hypoxemia (PaO_2 ≤45 mm Hg on room air)
- Unstable cardiac arrhythmia or stroke
- Pulmonary hypertension (sPAP>45mg Hg)

- Active smoker
- $PaCO_2$ > 55 mmHg or PaO_2 < 45 mmHg on room air
- BMI < 15 kg/m^2
- Hospitalized for COPD exacerbation or respiratory infections < 3 months
- Bronchitis; sputum production > 4 tbps/day
- Active asthma
- Giant bullae > 1/3 volume in either lung
- Severe pulmonary hypertension
- Prior major lung procedures (lobectomy or greater)
- ASA Class greater than 4

Airflow measurement

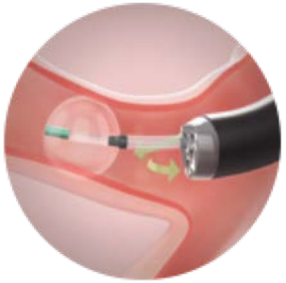

Balloon catheter inserted through a bronchoscope to the target airway, and the balloon is inflated to block flow to the target

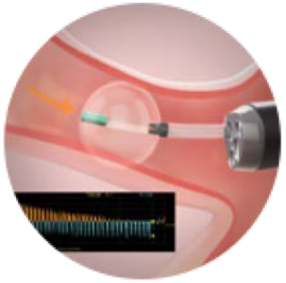

System calculates airway resistance and measures CV. Displays expiratory air flow (orange), pressure (blue), and resistance measurements

Detecting Collateral Ventilation

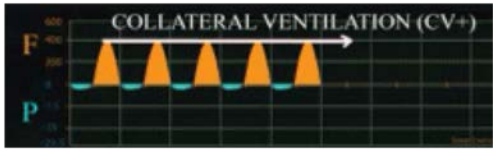

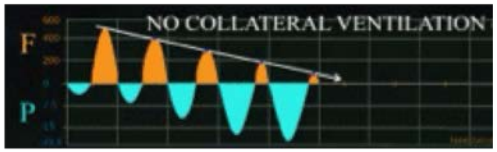

Endobronchial Valve Therapy in Patients with Homogeneous Emphysema: Results from the IMPACT Study

- 93 patients with homogeneous emphysema were confirmed CV negative
- Randomized 1:1 to EBV or medical management.
- Target lobes selected based on emphysema destruction scores and regional perfusion impairments
- 17% increase in FEV1, $p=0.002$ (primary outcome in intention-to-treat population)
- 40 m increase in 6MWD ($p=0.02$)
- Decreases in SGRQ ($p<0.0001$) and RV ($p=0.01$)
- Pneumothorax in 25.6%

Valipour et al. Am J Respir Crit Care Med 2016; 194(9): 1073-82

A Multicenter Randomized Controlled Trial of Zephyr Endobronchial Valve Treatment in Heterogenous Emphysema (LIBERATE)

- 190 subjects randomized (2:1) at 24 sites
- Primary outcome (at 12 months): 48% EBV and 17% SoC subjects had increase in FEV1 ≥ 15% ($p < 0.001$)
- Secondary outcomes showed statistically significant improvements:
  - 6MWT
  - SGRQ
  - Decrease in RV
  - Modified Medical Research Council Dyspnea Scale
  - BODE
- Pneumothorax 26.6% (procedure to 45d)

Criner et al. Am J Respir Crit Care Med 2018; 198(9): 1151-1164

Case 6

HPI

- 67 year old male with right-sided secondary spontaneous pneumothorax and persistent air leak after chest tube placement.
- 12 days later, he had a VATS with doxy and mechanical pleurodesis with 3 chest tubes placed. He had 2 CTs removed.
- Remained on wall suction for **6 weeks** at -30 with continuous air leak. On water seal, he developed worsened pneumothorax with severe subcutaneous emphysema.

CXR after VATS

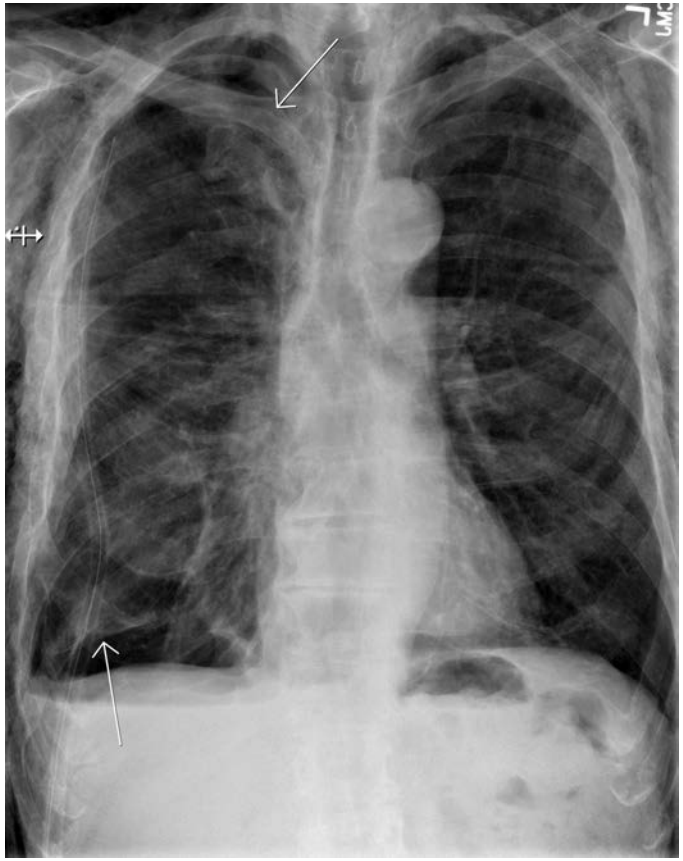

Which of the following is the best next option?

- A. Repeat thoracic surgery
- B. Attempt endobronchial valves
- C. Blood patch
- D. Discharge home with a one-way valve (Heimlich)

Persistent air leak

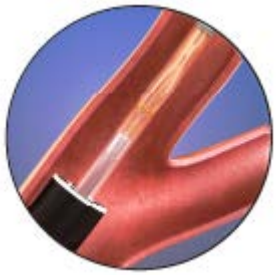

Placed Valve in RB6

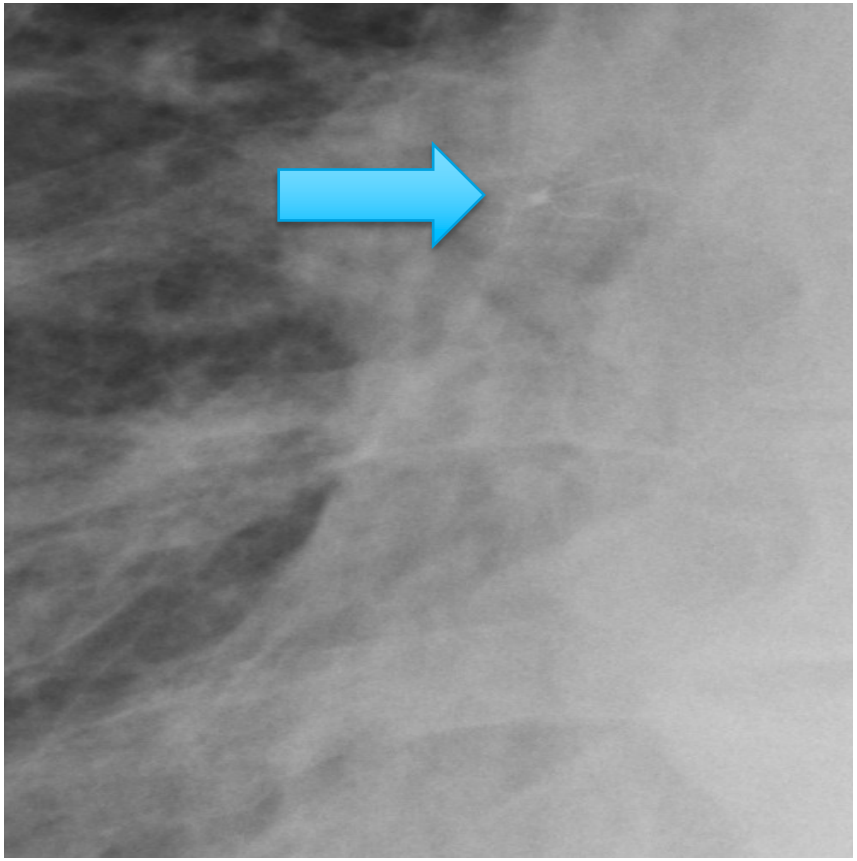

Air leak resolved, chest tube removed, and patient D/C home.

Treatment of persistent pulmonary air leaks using endobronchial valves.

- Prospective trial at 17 international sites
- 40 patients
- 1 to 9 endobronchial valves per patient
- Recurrent spontaneous pneumothorax (n = 21), postoperative (n = 7), iatrogenic (n = 6), first-time spontaneous pneumothorax (n = 4), bronchoscopic lung volume reduction (n = 1), and trauma (n = 1)
- **Nineteen patients (47.5%) had a complete resolution of the air leak, 18 (45%) had a reduction**, 2 had no change, and 1 had no reported outcome.
- The mean time from valve insertion to chest tube removal was 21 days and from valve procedure to hospital discharge was 19 +/- 28 days (median, 11 days; IQR, 4 to 27 days).

Traveline et al. Chest 2009 Aug;136(2):355-360

Significant benefits in case series like this one

- During a 15-month period, 8 valve placement procedures were performed in 7 patients and all had improvement in the air leak.
- The median duration of air leakage was 4 weeks before and 1 day after treatment, with a mean of 4.5 days
- Discharge within 2 to 3 days of procedure in 57% of the patients
- Median of 3.5 valves and all valve removals were successful
- No procedural or valve-related complications.

Gillespie CT, et al. Ann Thorac Surg 2011;91:270-3

Conclusions

- Patients with malignant CAO should be evaluated for palliative endobronchial procedures.
- Centers performing these procedures should offer a multi-modality/multi-disciplinary approach to endobronchial therapy including the availability of rigid bronchoscopy.
- Select patients with severe emphysema and hyperinflation may benefit from endobronchial lung volume reduction though pneumothorax is a significant complication.
- Endobronchial valves are indicated in prolonged post surgical air leaks and may be considered for other cases of persistent air leak.

Acknowledement

Gerard J. Criner, M.D.

Professor and Chair, Department of Thoracic Medicine and Surgery

Lewis Katz School of Medicine at Temple University

Philadelphia, PA